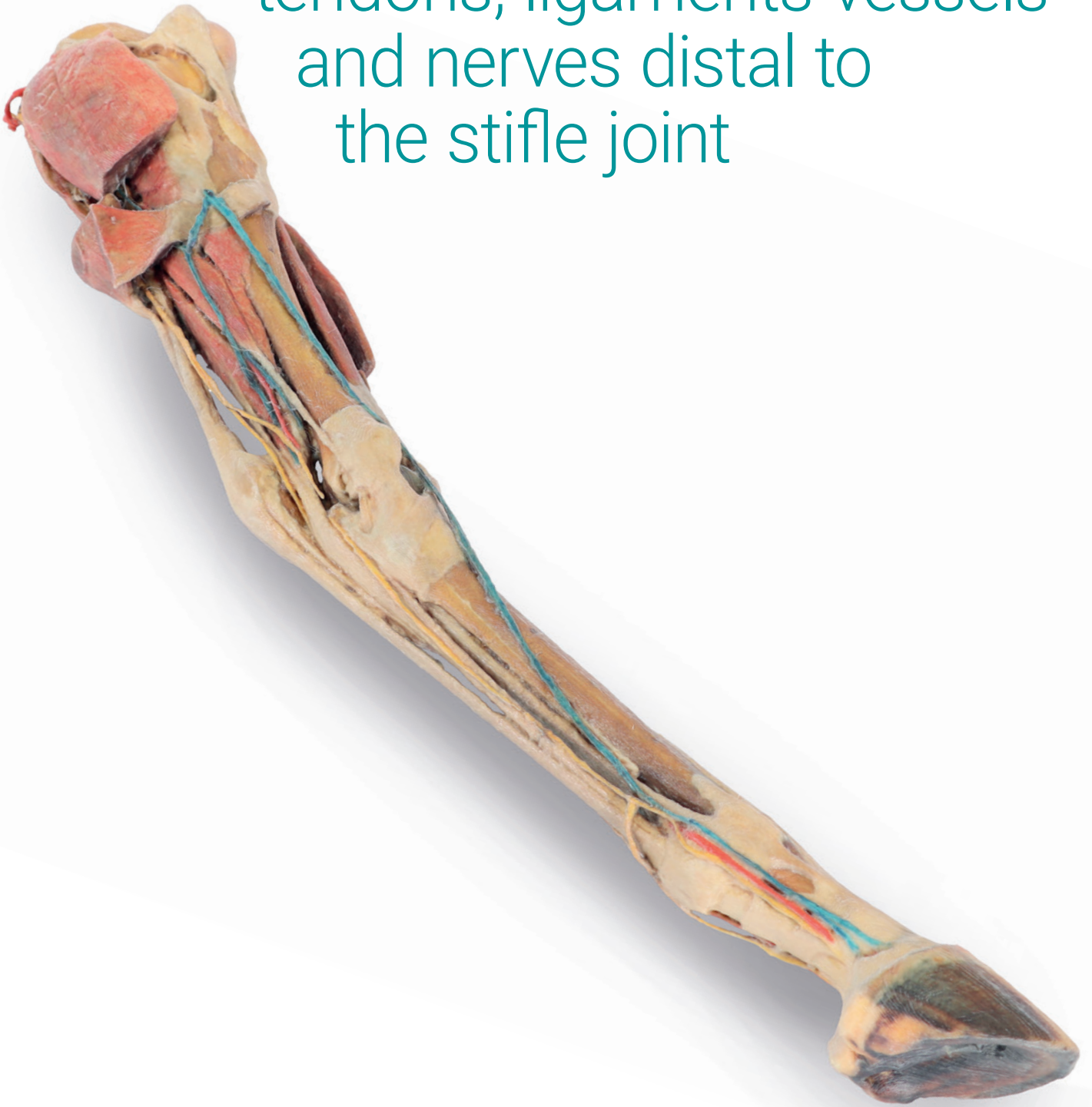


Horse hindlimb – muscles,
tendons, ligaments vessels
and nerves distal to
the stifle joint



Item No. VP10050

Horse hindlimb - muscles, tendons, ligaments, vessels and nerves distal to the stifle joint

This specimen preserves a superficial dissection of the lower limb musculature from the mid thigh to the hoof. The capsule of the stifle and tarsus joints has been opened to demonstrate the menisci, the main ligaments and the topography of the tendons. Muscles extensor and flexor of these joints as well as the foot joints have been dissected from the origin in the femur and tibia bones, to the insertions tendons in the tarsus, metatarsus and phalanges bones. Nerves and vessels have been dissected in the popliteal fossa, tarsus and digit regions. Detailed anatomical description on request.

