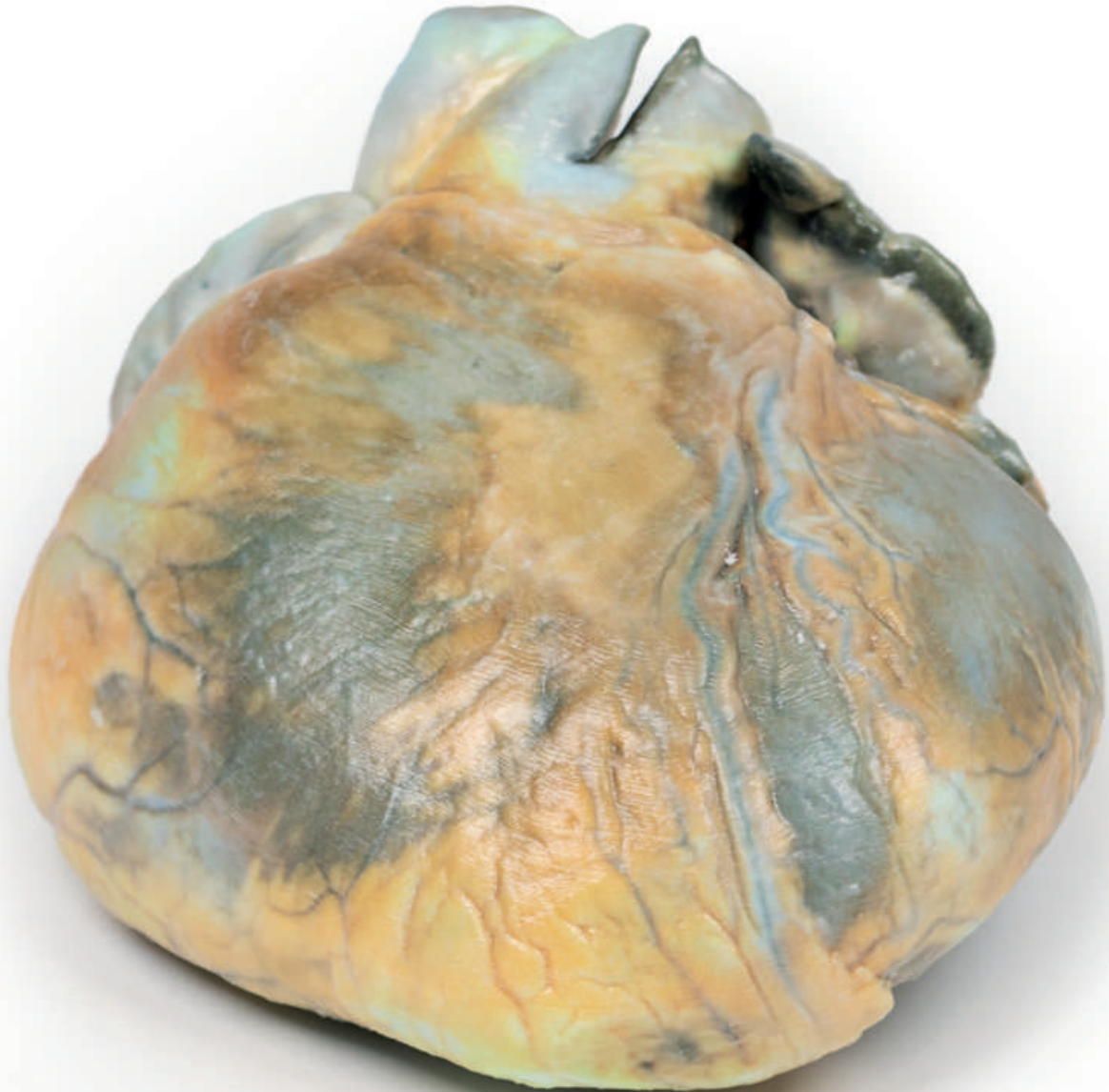


# Right Ventricular Hypertrophy (RVH)



Ref.no.: MP2031

# Right Ventricular Hypertrophy (RVH)

## Clinical History

This 56-year old female suffered from emphysema and gave a 2-year history of increasing shortness of breath on exertion associated with recurrent attacks of bronchitis. On examination, she had a BP 160/90 mm Hg, pulse rate of 96 beats/min, and 6 cm of jugular venous congestion. The apex beat was impalpable, bilateral crepitations were heard and pitting oedema was present peripherally. Special investigations: ECG showed right heart strain pattern. Arterial blood examination showed respiratory acidosis. Despite treatment there was steady deterioration and death.

## Pathology

The specimen is of the external surface of the heart viewed from the anterior aspect. The right ventricle is greatly enlarged and hypertrophied. All appears to be normal otherwise. This is an example of right ventricular hypertrophy (RVH) in a patient with emphysema.

## Further Information

RVH usually occurs due to chronic lung disease or structural defects in the heart. One of the most common causes of RVH is pulmonary hypertension (PH), which leads to increased pulmonary artery pressure. As the right ventricle tries to compensate for this increased pressure it changes its shape and size causing hypertrophy and right ventricular wall thickness. The global incidence of PH is 4 per 1M people: RVH occurs in approximately 30% of these cases. Common causes of PH include chronic obstructive pulmonary disease (COPD), pulmonary embolism, and other restrictive lung diseases. RVH also occurs in response to structural defects in the heart, such as tricuspid insufficiency, which allows the backward flow of blood into the ventricle. Other structural defects that lead to RVH include tetralogy of Fallot, ventricular septal defects, pulmonary valve stenosis, and atrial septal defects. RVH is also associated with abdominal obesity and high systolic blood pressure.

