Female right pelvis superficial and deep structures

Ref.no.: MP1783

ERLER ZIMMER
MEDICAL

Female right pelvis superficial and deep structures

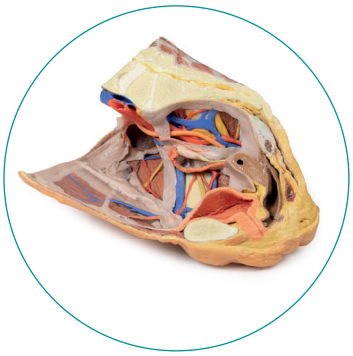

This 3D printed female right pelvis preserves both superficial and deep structures of the true and false pelves, as well as the inguinal ligament, the obturator membrane and canal, and both the greater and lesser sciatic foramina. Somewhat unique is the removal of portions of the peritoneum (a grayish colour) to create 'windows' displaying extraperitoneal structures.

The specimen has been sectioned transversely through the L4 vertebra, displaying a cross section of the colon, the epaxial musculature (psoas and quadratus lumborum muscles), and the abdominal wall musculature. The common iliac artery has been preserved from the level of the L4 vertebra, and its bifurcation into the external and internal iliac arteries can be observed at the level of the sacral promontory. Deep to the arteries the common iliac vein and the origin of the inferior vena cava are visible.

The external iliac artery and vein passes anteroinferiorly along the pelvic brim, giving rise to the inferior epigastric and deep circumflex arteries and veins before passing deep to the inguinal ligament. The psoas major muscle lies lateral to the external iliac artery, with the femoral nerve evident on its lateral margin close to the inguinal ligament. The lateral cutaneous nerve of the thigh travels laterally on the superficial surface of the iliacus muscle to exit the 'false' pelvis close to the anterior superior iliac spine.

Following the course of the internal iliac artery deep to the undissected peritoneum, many of the major branches of its anterior and posterior divisions can be identified. The anterior division divides (deep to the peritoneum) into the superior vesical, obturator and obliterated umbilical artery. With a course parallel to the obturator artery, the obturator nerve can be seen running over obturator internus before entering the obturator canal together with the obturator vein (nerve, artery, vein in that order from superior to inferior).

Branches of the posterior division of the internal iliac artery, iliolumbar, and several lateral sacral arteries, can be seen arising from the posterior aspect of the internal iliac just below the sacral promontory. Its terminal branch, the superior gluteal, usually passes posteriorly between the lumbosacral trunk and S1 nerve, but this is hidden from view. The internal iliac vein and its tributaries - the obturator veins, uterine vein, vesical veins, etc. can be seen lying internal to the nerves and muscles. The large S1 and S2 roots and the smaller S3 nerve root can be seen emerging from the sacral foramina to pass laterally where it is joined by the lumbosacral trunk (L4 and l5 roots) which is not visible, to form the sciatic nerve which exits through the greater sciatic foramen to emerge on the posterior aspect in the gluteal region. In the pelvis as these roots pass laterally they are interdigitated between the fibres of piriformis muscle.

The right ureter can be clearly seen as it passes inferiorly on the posterior abdominal wall superficial to psoas muscle. It passes over the pelvic brim at the bifurcation of the common iliac artery to descend on the lateral wall of the pelvis before passing medially in the base of the broad ligament (hidden from view as the peritoneal folds that 'drape' over the uterine [Fallopian] tubes are still intact) to reach the lateral angles of the bladder.

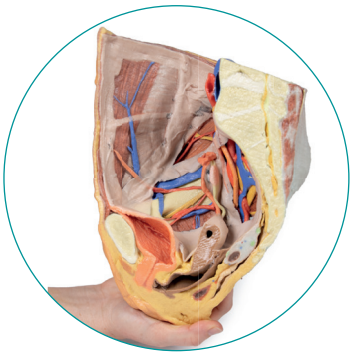

In the pelvis the viscera which lies most anteriorly is the bladder. Its thick wall and cavity is easily seen in this mid-sagittal cut. Indeed the ureteric orifice can be seen at the angle of the trigone of the bladder on its internal mucosal surface. The relations of the uterus to the vagina are clearly visible in the mid-sagittal section. Indeed the anterior and posterior fornices are clearly seen as is the os of the cervix. The round ligament of the uterus has been removed along with some peritoneum to display the structures in the lateral pelvic wall. The entire right Fallopian tube is identifiable as it passes from the lateral aspect of the body of the uterus to terminate as the fimbria which overhangs the right ovary which is still held in place by its mesovarium. The ovary is attached laterally to the pelvic brim by the suspensory ligament of the ovary (sometimes called the infundibulopelvic ligament) which contains its named artery and veins. The ligament of the ovary is clearly visible leading from the medial aspect of the ovary to the lateral surface of the uterus.

There are only small cut surfaces of the rectum (visible as little islands of mucosa) visible on the sagittal cut surface suggesting that it is slightly off the midline plane. Some pararectal lymph nodes (coloured pale green) can be seen close to these islands of rectal mucosa.

On the anterior aspect of the 3D print the inguinal ligament has been retained and deep to it the femoral artery, vein and nerve pass to the anterior compartment of the thigh.

In the gluteal region (note the femur has been removed to expose the acetabulum) the sciatic nerve can be seen emerging from the greater sciatic foramen (GSF) alongside the inferior gluteal vessels below the remains of the piriformis fibres, whereas the superior gluteal vessels and nerve emerges above the piriformis. Below these vessels the pudendal nerves and vessels can be seen exiting the GSF and passing over the sacrospinous ligament to enter the lesser sciatic foramen, thereby entering the perineum along the lateral wall of the ischioanal fossa.